

Biologic Tissue Scaffolds in Shoulder Surgery

Implant surgery for previously inoperable rotator-cuff tears

By **Nina Silberstein**

A major development in shoulder surgery, the arthroscopic delivery of biologic scaffolds for rotator-cuff repair, is now a reality. For patients with inoperable rotator-cuff tears, the implants and techniques involved appear promising, based on clinical experience gained over the past 2 to 3 years. Two orthopedists have been among the first to perfect arthroscopic rotator-cuff repair using tissue scaffolds.

Stephen J. Snyder, MD, specializes in arthroscopic surgery and reconstructive procedures of the shoulder joint at the Southern California Orthopedic Institute, Van Nuys,

Calif. His technique employs an allograft¹ derived from cadaver skin that has been processed (using patented methods) to remove the epidermis and the dermal cells, but to retain the intact collagen matrix with preserved vascular channels. Richard Seldes, MD, is director, department of orthopedics, Forest Hills Hospital, Queens, NY. He uses a xenograft² made of fetal bovine dermis that has undergone a patented production process that transforms it into a scaffold of acellular, nondenatured collagen.

ROTATOR-CUFF REPAIR

Rotator-cuff tears, common in people more than 40 years old, are associated with participation in sports, with work-related overhead repetitive motion, and with acute trauma (including shoulder fractures and dislocations). Typical symptoms of rotator-cuff injury are pain at the front of the shoulder that radiates down the side of the arm, pain when lifting the arm to (or lowering it from) a fully raised position, stiffness, loss of motion, and a snapping sensation. Following a physician's examination, the diagnosis of rotator-cuff injury is made using strength testing and an MRI study.

Surgery to repair the rotator cuff is often advised when a rotator-cuff tear causes severe shoulder weakness or, in less severe cases, when there has been no improvement following nonsurgical treatment (typically consisting of some combination of resting, taking anti-inflammatory medication, limiting overhead activity, using a sling, having steroid injections, using strengthening exercises, and undergoing physical therapy).

Traditional (open) surgery to debride and repair a torn rotator cuff can require an incision at the top of the shoulder, and this may be 10 to 15 cm long. The deltoid muscle must be removed from its insertion point and reattached at the close of the procedure, and this can be traumatic. A second open procedure, the mini-open technique, splits the deltoid to provide surgical access to the rotator cuff. Because the incision is smaller, healing is likely to be more rapid than it is following the traditional repair.

Because arthroscopic repair is minimally invasive, involving only the small incisions needed to insert the arthroscope and the necessary miniaturized surgical instruments, trauma is minimized and healing is generally superior.

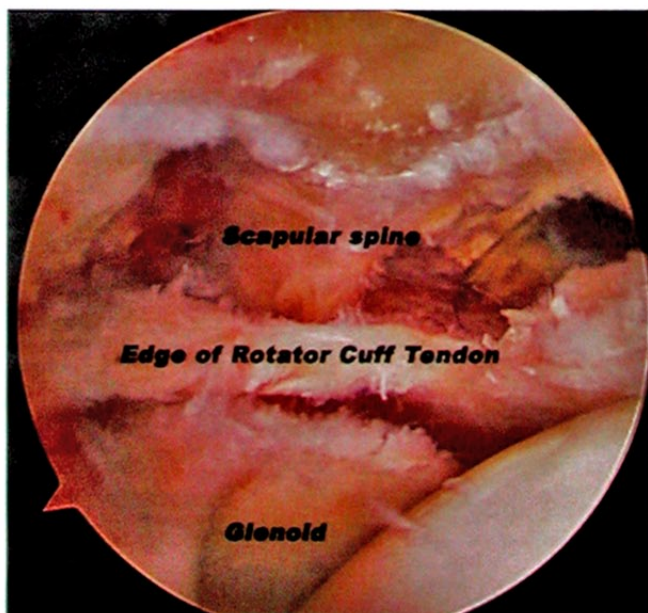


Figure 1. Intraoperative view of a massive rotator cuff tear before repair with the cadaver allograft.¹ The edge of the cuff is retracted to the level of the glenoid and spine of the scapula. Image courtesy of Stephen J. Snyder, MD, Southern California Orthopedic Institute, Van Nuys, Calif.

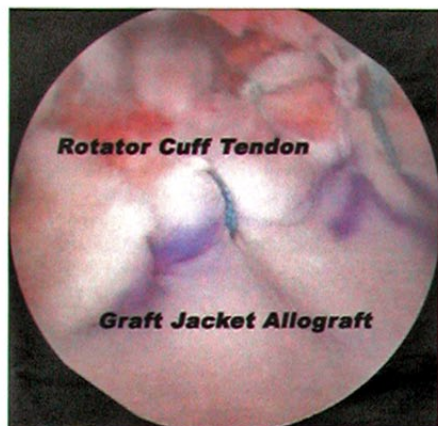

Figure 2. View in surgery of Graft Jacket installed to fill defect in rotator cuff. Image courtesy of Stephen J. Snyder, MD, Southern California Orthopedic Institute, Van Nuys, Calif.

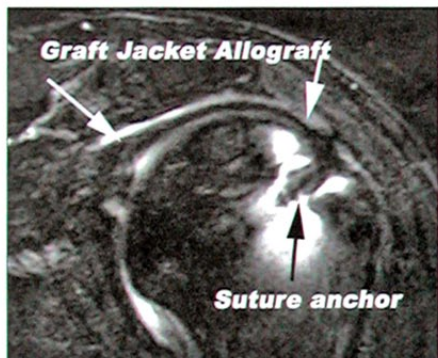


Figure 3. Postop MRI at 1 year showing good healed cuff and muscles. Image courtesy of Stephen J. Snyder, MD, Southern California Orthopedic Institute, Van Nuys, Calif.

All techniques for rotator-cuff repair, however, have been unsuitable for patients with inadequate soft-tissue mobility (short tendons) or poor tissue quality. In these cases, previously considered inoperable, and for patients whose prior rotator-cuff repairs have failed, the use of the cadaver allograft or bovine xenograft may make the restoration of shoulder function possible for the first time.

ARTHROSCOPIC IMPLANTS

The bovine xenograft,² a collagen membrane that is used to repair deficits and reinforce soft tissues, is indicated for repair of the rotator cuff. This implant, placed arthroscopically, is designed to serve as a scaffold for cellular remodeling over time and will have become host tissue by the time that healing is completed. Native fibroblasts will occupy the collagen fibers of the xenograft, and angiogenesis will be encouraged. "The ideal patient would be someone with a large tear (greater than 2 to 3 cm) or an older patient with a chronic tear," Seldes explains.

Snyder founded the International Shoulder Arthroscopy Study Group and sits on the board of directors of the Arthroscopy Association of North America. The allograft¹ that he uses (Figures 2, 3) retains the native elastin, proteoglycans, basement membrane, and vascular channels. The extracellular framework, being intact, supports rapid cellular repopulation and revascularization (through a mechanism known as inosculation). The allograft is indicated for the

repair of rotator-cuff tears and diabetic foot ulcers, as well as to reinforce primary soft-tissue repairs of the anterior shoulder capsule, Achilles tendon, and quadriceps tendon.

According to Snyder, the graft must have the necessary strength and ability to attract and house the stem cells that will then be transformed into fibroblasts; it must also have channels for blood vessels and a covering that will continually refresh the tissue and build a new rotator cuff. "It also has to have enough elasticity

to prevent suture pullout, and an ability to encourage ingrowth of blood vessels," he says. The allograft is still in the preliminary stages of evaluation, but histology supports that it promotes rapid revascularization and carries a low risk of rejection.

TECHNIQUES

Snyder has pioneered the technique for placing the allograft arthroscopically for the treatment of irreparable rotator-cuff tears. He

stryker

TissueMend® Soft Tissue Repair Matrix

Your Choice for Tendon Augmentation



Confidence

Strength

Results

When implanted, TissueMend® provides an environment that host cells and supporting vasculature can take up residence and mature. Over time, normal tissue remodeling occurs where TissueMend® is incorporated into the native tissue and ultimately replaced by natural, healthy native cells and tissue.

For more information, please contact your local Stryker Orthopaedics Sales Rep or visit www.stryker.com/tissuemend.

TissueMend®

Stryker Orthopaedics 325 Corporate Drive, Mahwah, NJ 07430

A surgeon is the best person to decide with the patient which treatments and products are right for them. Surgeons must always rely on their own clinical judgment when deciding which treatments and procedures to use with patients. TissueMend® is a registered trademark of TEI Biosciences, Inc. Copyright © 2005 Stryker

describes arthroscopic implantation as "such a revolutionary approach to an otherwise unsolvable problem. It is good for irreparable tears on an otherwise good shoulder, without arthritis," he says. "The problem, for whatever reason, is that the rotator cuff has failed and cannot be repaired by standard methods. It is indicated for

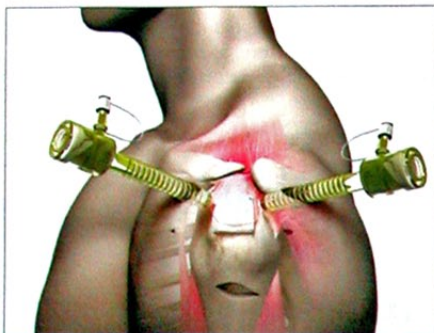

Figure 4. (above) Arthroscopic repair of rotator cuff, using bovine xenograft,² in progress.

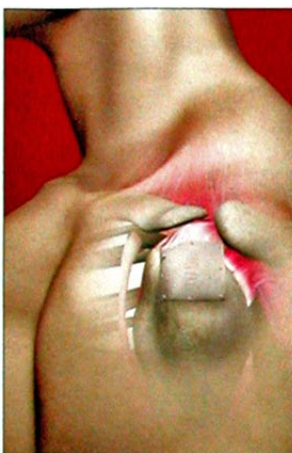

Figure 5. (left) Bovine xenograft² in place.

Special stitches are run outside and inside the body, and suture anchors are affixed to the bone. The sutures are run out through the allograft and pulled in to position it. Some additional stitches are made around the allograft's edge.

The method employed by Seldes also involves inserting a collagen patch (in this case, a bovine xenograft) that

combines with a patient's own tissue and enhances healing through minimally invasive surgery. "We do not have to remove the muscle," Seldes says. "There is less pain, less stiffness, and earlier recovery." The procedure takes about 2 hours, and the patient can go home the same day.

RESULTS

To date, Seldes has performed about 15 similar surgeries over the course of a year. Recovery time following repair using the xenograft can require from 4 to 6 weeks in an immobilizer, followed by an additional 3 to 6 months of physical therapy. Patients undergoing this procedure have regained 75% to 90% of their preinjury levels of use of the shoulder, depending on other factors such as age and extent of damage. "Any time you do surgery, there are risks," Seldes notes. "Any time you make a skin incision, there is a chance of bleeding, infection, or nerve damage, and sometimes the shoulder can get stiff."

For the xenograft itself, Seldes says that he has not seen any specific complications, although patients are being followed closely. "The success rate looks good," he says. "Certainly, these patients who were miserable before are starting to function. It looks pretty promising."

Snyder has performed 21 arthroscopic rotator-cuff repairs using the cadaver allograft over a 2-year period and believes in the technology. The beauty of the procedure, he reports, is that, with the new allograft, patients heal much more rapidly and can enter rehabilitation sooner. Snyder has a rigorous postoperative protocol that includes MRI

Xenograft Testimonial

Following an injury to his shoulder resulting from a fall, 70-year-old Ron Russo, New York City, could perform certain movements, but his shoulder was not fully functional. "I could not really lift it," Russo says. "It was just like a dangling piece of meat." After nonsurgical treatments were explored, Russo was referred to Richard Seldes, MD, director, department of orthopedics, Forest Hills Hospital, Queens, NY. Russo decided to undergo arthroscopic repair using a bovine xenograft.¹

Russo is pleased with the results of surgery. He says, "I have about 95% of the range of motion and about 40% of the strength" that he had before his injury. Russo intends to begin vigorous work to restore the remaining strength deficit as soon as Seldes confirms (using ultrasonography) that the repair has healed. Because it can take 9 months for the patient's own tissue

to combine with the xenograft, Russo has been told to defer strenuous activity until healing is complete.

He reports that the surgery has helped him tremendously. "I look at my shoulder in the mirror and would not even think that I have had surgery. It is amazing, really," he says. "I am not physically active with sports or anything like that, but I am active in doing handy things around the house, being with my kids, and what have you. It is like a new lease on life."

REFERENCE

1. Stryker. Product overview: biologics: Stryker TissueMend® soft tissue repair matrix. Available at: <http://www.stryker.com/jointreplacements/sites/tissuemend/index.php>. Accessed November 3, 2005.

patients in good health who are nonsmokers, without infection or diabetes."

During the 2.5-hour surgery that Snyder performs, the defect is measured arthroscopically and the allograft is cut to the size needed.

examination 3 months after the procedure to confirm graft incorporation.

CONCLUSION

Seldes is optimistic about the bovine xenograft and sees it as an integral part of the equipment and methods used to treat difficult cases. "This scaffold has great potential in light of the increased emphasis on using gene therapy and growth factors to heal rotator-cuff tears," he says. "In the future, it might be a good carrier for those types of therapies."

Arthroscopic rotator-cuff surgery has been available for several years, as has the collagen patch to repair soft tissues; now, the two have been combined. OR

DISCLOSURE

Richard Seldes, MD, serves as a consultant to Stryker, Kalamazoo, Mich. Stephen J. Snyder, MD, serves as a consultant to Wright Medical Technology Inc, Arlington, Tenn.

REFERENCES

1. Wright. Physicians: biologics: GRAFTJACKET® rotator cuff tendon reinforcement scaffold. Available at: <http://www.wmt.com/Physicians/Products/Biologics/GRAFTJACKETRotatorCuff.asp>. Accessed November 3, 2005.
2. Stryker. Product overview: biologics: Stryker TissueMend® soft tissue repair matrix. Available at: <http://www.stryker.com/jointreplacements/sites/tissuemend/index.php>. Accessed November 3, 2005.

Allograft Testimonial

Orthopedic surgeon Steve Wasilewski, MD, Ketchum, Idaho, who had experienced minor shoulder injuries in the past, suffered a massive tear of his rotator cuff while playing golf. The 55-year-old man underwent an initial arthroscopy that revealed that the tear was irreparable using conventional techniques. He was unable to participate in the many recreational activities that he had always enjoyed. In addition, he says, "I was having problems with activity-related pain, with performing surgery on my own patients, and with weakness of the shoulder with activity."

Wasilewski considered treatment options such as rehabilitation and activity modification, tendon transfer, and tendon advancement. Based on his own experience and research, he chose to have a cuff-replacement procedure using a cadaver allograft¹ performed by Stephen J. Snyder, MD, Southern California Orthopedic Institute, Van Nuys, Calif. "The procedure was not as invasive as other options and,

in my opinion, offered a much better risk-reward profile," Wasilewski explains.

During his 4-month recovery following the procedure, he was unable to perform surgery. Now, 15 months after surgery, he is able to work without discomfort, and has performed the same procedure on some of his own patients. He has also resumed his recreational activities. "I have returned to playing golf, skiing, windsurfing, and other recreational activities using my arm," Wasilewski says. "I am not as strong as I was prior to the injury, and I do not have the same endurance for work and activities, but I have significantly benefited from the surgery."

REFERENCE

1. Wright. Physicians: biologics: GRAFTJACKET® rotator cuff tendon reinforcement scaffold. Available at: <http://www.wmt.com/Physicians/Products/Biologics/GRAFTJACKETRotatorCuff.asp>. Accessed November 3, 2005.